

**Forensic Mental Health Services
Managed Care Network**



**Frontotemporal Dementia
Educational Resource**

School of Forensic Mental Health

The School of Forensic Mental Health (SoFMH) was established in late 2007. It is currently hosted by the Forensic Mental Health Services Managed Care Network and has formal links with the Universities of Edinburgh, Stirling and Glasgow Caledonian. It offers teaching and training to all professional groups and staff involved in the assessment and care of mentally disordered offenders and others requiring similar services. It provides a focus for supporting, developing and delivering multi-disciplinary and multi-sector educational and research initiatives.

Biography

Dr Julie Snowden is a consultant neuropsychologist and honorary reader in the Cerebral Function Unit, a multidisciplinary specialist unit for early onset dementias, in Greater Manchester Neuroscience Centre, Salford Royal Foundation Trust. Frontotemporal dementia and other focal dementia syndromes are her principle research interest.

Contents

Preface	3
Introduction	4
FTD Clinical Overview	4-6
<ul style="list-style-type: none"> • Demographics • Behaviour: social conduct and affect • Behaviour: stereotypes • Behaviour: hyperorality and dietary change • Cognition: executive impairments • Cognition: language, memory, and spatial skills • Physical changes • Electrophysiology and Neuroimaging 	
Neuropathology and Genetics	7
Phenotypic variation: apathetic, disinhibited and stereotypic forms of FTD	7
Related clinical syndromes: Progressive aphasia and semantic dementia	7-8
Nomenclature and Nosology	8
Diagnostic challenges in FTD	8-9
<ul style="list-style-type: none"> • Youthful onset • Slow course • Affective presentation • Psychotic presentation 	
FTD and the law	9
Commentary on the Mental Health Commission Report of Mr G	10
Cognitive Assessment	11-13
<ul style="list-style-type: none"> • Cognitive screening instruments • Frontal assessment batteries • 'Bedside' Assessment of Frontal Lobe function 	
Case Histories	14-15
Clinical Diagnostic Criteria for FTD – Box 7	16
Further reading	17-21
Multiple choice questions and answers	22-25

Preface

By definition rare conditions such as frontotemporal dementia (FTD) are, for most of us, seen only occasionally during the course of a clinical career. On those occasions, it is important that our index of suspicion is raised so that we seek out appropriate tests and advice to guide our assessment and management. This educational resource was designed as a brief guide to and revision tool for FTD.

It was prompted by the Mental Welfare Commission's report on the sad case of Mr G who was rejected by services on the grounds of a diagnosis of personality disorder, rather than FTD, and who ended up in prison. A recommendation contained within the report was that an educational resource should be made available to all psychiatrists and other clinicians.

I would like to thank our principle author, Julie Snowden, for producing a practical and informative guide to FTD brought to life by clinical cases and the opportunity for self-assessment MCQs; and colleagues from the Royal College of Psychiatrists, the Mental Welfare Commission, neurology and the Mental Health Division of the Scottish Government for their assistance in preparing this resource. We trust that you will find it useful.

An electronic version of this resource can be found at:

www.sofmh.scot.nhs.uk

Dr Lindsay Thomson
SoFMH
October 2009

Produced in association with



Introduction

Frontotemporal Dementia

The development of this educational resource has been prompted by the case of Mr G, who was the subject of an investigation by the Mental Welfare Commission for Scotland. Mr G had contact with mental health services between 2001 and 2004 and during that time his increasingly inappropriate behaviour was ascribed to personality disorder. The Commission became involved with Mr G while he was in prison in 2004, concerned about the appropriateness of his placement and deficiencies in his past care and treatment. The conclusion from the Commission's investigation was that Mr G suffered, not from a personality disorder, but rather from frontotemporal dementia (FTD), a degenerative disease of the frontal and temporal lobes of the brain associated with disordered behaviour and judgement, and that there had been deficiencies in his care. Mr G died in hospital in 2006.

The purpose of this resource is to raise awareness of FTD and improve its recognition by psychiatrists. The materials describe the clinical characteristics of FTD, and highlights areas of diagnostic challenge. It discusses the circumstances in which patients might be seen in forensic practice, and comments on the case of Mr G, as described in the Commission's report. Formal neuropsychological assessment plays an important role in the clinical diagnosis of FTD. However, such assessment may not always be readily available. Simple 'bedside' tests are described that require minimal resources and could be used by psychiatrists in many settings, including prison to provide pointers to frontal lobe disturbance, providing the foundation for more extensive investigations. Case histories are provided, one applicable to general psychiatry and two relevant to forensic practice.

FTD: Clinical Overview

Demographics

Frontotemporal dementia (FTD) is the second most common form of early onset degenerative dementia after Alzheimer's disease. It affects men and women equally. Onset is usually between the ages of 45 and 65 years although older and younger presentations do occur, the youngest recorded onset in a pathologically confirmed case being 21 years. Symptoms progress inexorably. The rate of decline is highly variable, the duration from onset to death ranging from 2 to 20 years, with a median of 8 years. The disorder is strongly familial, a similar dementing illness in a first-degree relative being reported in up to 40% of cases. There are no known geographical, cultural or environmental determinants of disease

Box 1

Clinical Overview

- Early onset dementia
- Strongly familial
- Striking behavioural and personality change
- Physically well early
 - parkinsonism late
- Frontal and temporal lobe atrophy on imaging

Behaviour: social conduct and affect

The salient, defining characteristic of FTD is a radical alteration in the patient's personality and social conduct, reflecting the degeneration of the frontal lobes. Formerly caring and responsible citizens become disinhibited and socially inappropriate, lacking in sympathy, empathy or concern for others. They neglect self-care, domestic and occupational responsibilities, and have no insight into their altered mental state. They may become incontinent without embarrassment. Because of the insidious evolution of the disorder the precise onset is hard to define. Nevertheless, the symptoms that cause families to be aware that something is wrong are most commonly in the realm of social behaviour or affect: uncharacteristic lack of manners and social courtesies at a social occasion; lewd remarks; a lack of expression of grief at the death of a loved one.

Behaviour: stereotypies

Alterations in social conduct and affect dominate the clinical picture. However, there are other changes that are important diagnostically because of their high sensitivity, being reported in at least 50% of cases and specificity, occurring rarely in other forms of dementia such as Alzheimer's disease and vascular dementia. Repetitive/stereotyped behaviours represent one such area of change. Repetitive behaviours in FTD may constitute simple motor mannerisms, such as repetitive humming, tapping, grunting, hand rubbing. They may include more complex activities such as pacing, wandering a fixed route, repeated use of a favoured word or saying, repeated clapping of the same rhythm, repeated singing of the same song, and hoarding objects. Some patients adhere to a fixed daily routine.

Behaviour: hyperorality and dietary change

Another behavioural domain with high discriminating value is orality. FTD patients frequently showed altered dietary habits. They may become gluttonous, cram food, and steal from other people's plates, and drink or smoke to excess. Other patients exhibit food fads. Commonly, there is an altered preference for sweet foods, and patients may seek out and hoard sweets, cakes and biscuits. In the later stages patients may put inanimate objects into their mouth.

Cognition: executive impairments

Patients exhibit impairments in a range of executive/control functions that depend on the function of the frontal lobes. These include impairments in planning, foresight and judgement, organisation and sequencing, attention, abstraction, self-monitoring and checking and mental flexibility. Neuropsychological assessment may elicit deficits in each of these domains. Patients commonly perform poorly on tasks that require forward planning (e.g. Tower of London test). They fail tasks involving organisation and sequencing (e.g. picture arrangement). They show poor sustained, divided and selective attention and impaired response inhibition (e.g. stroop test). They exhibit a concrete, literal mode of thought and have difficulty on tasks involving abstraction of a rule and shifting of mental set from one rule to another (e.g. Wisconsin card sorting test; Weigls' colour-form sorting test; Brixton spatial anticipation test). They show a high level of perseverative responses.

Box 2

Affect and Behaviour

- Emotional blunting, fatuousness
- Loss of sympathy and empathy
- Social disinhibition, impulsivity
- Restlessness, purposeless overactivity – apathy, inertia
- Self-neglect
- Repetitive behaviours, stereotypies
- Hyperorality, dietary change
- Loss of insight

Box 3

Cognition: executive impairments

- Economy of effort
- Lack of adherence to task goal - rule violations
- Concreteness of thought
- Poor sustained and selective attention
- Poor planning and sequencing
- Impaired mental set shifting
- Verbal and motor perseveration

Impairments in executive skills are reflected in patients' behaviour. They show a lack of productive, goal-directed behaviour. They may exhibit apathy and inertia, or else purposeless overactivity, flitting from one activity to another without completing tasks. They show poor organisational skills in activities of daily living. They may be overtly inattentive and distractible. They show mental rigidity and are poorly adaptable to changing circumstances.

Cognition: language, memory, and spatial skills

Patients often show reduced speech output, culminating ultimately in total mutism. This lack of generative speech is a product of patients' frontal lobe disorder. Echolalia, perseveration and verbal stereotypies, which are also frontal features, may also be present. When there is marked temporal as well as frontal lobe atrophy patients may have an additional disorder of naming resulting from semantic loss, and may use words incorrectly (e.g. "dog" for sheep). Memory is inefficient, because of poor motivation and lack of active use of strategies for learning, but patients are not severely amnesic. Patients perform most poorly on open-ended recall tasks requiring active generation of information, but may benefit from cues and recognition procedures. Spatial skills are well preserved, reflecting preservation of parietal areas: patients may be noted to wander the locality without becoming lost. They can align objects normally and negotiate their immediate environment.

Box 4

Cognition: general

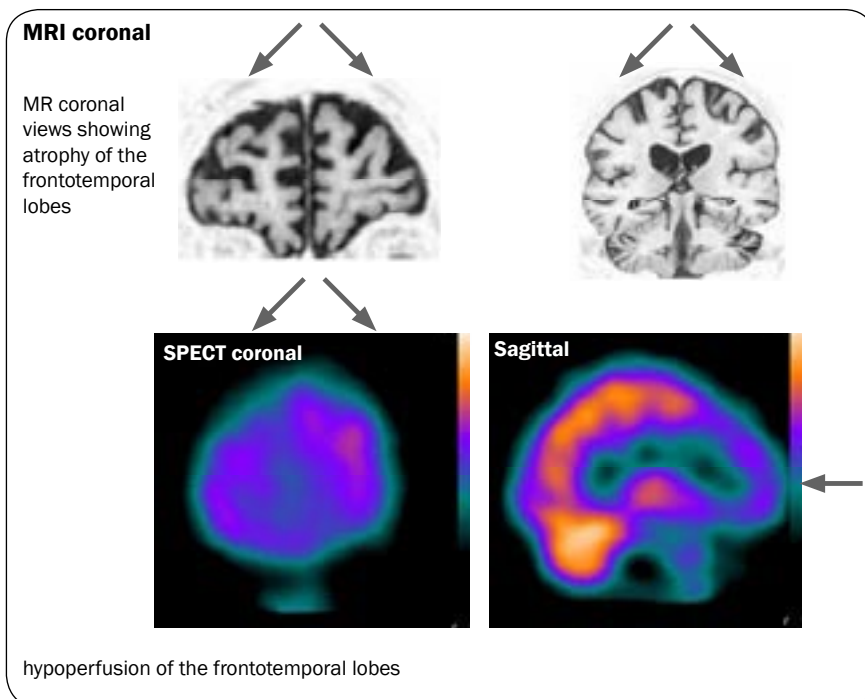
- Speech economy, echolalia, perseveration, stereotypies, word errors - mutism
- Preserved perceptuo-spatial skills
- Memory inefficient, especially free recall. No severe amnesia

Physical changes

FTD patients are typically physically well early in the disease course. However, parkinsonian signs of bradykinesia and rigidity develop later. Moreover, a proportion of FTD patients (about 10%) develop motor neurone disease (MND). Such patients have an attenuated course and die of the physical complications of MND.

Electrophysiology and Neuroimaging

Standard electroencephalography is unremarkable. Structural (MR) and functional (SPECT) imaging typically reveals atrophy/reduced perfusion in the frontal and/or temporal lobes (see figures). Changes are usually bilateral, although may be asymmetric, with emphasis on either the left or right side. A normal scan, reported in about 10% of cases, or the presence of generalised atrophy with no frontotemporal emphasis does not preclude the diagnosis, although suggests a need for diagnostic caution. Sensitivity is slightly greater for functional (SPECT) than structural (MR) imaging, although specificity is reduced: frontotemporal hypoperfusion on SPECT is sometimes also seen in psychosis. Imaging changes need to be interpreted in the context of clinical history, physical and cognitive examination. Electromyography is valuable in confirming the presence of MND.



Standard electroencephalography is unremarkable. Structural (MR) and functional (SPECT) imaging typically reveals atrophy/reduced perfusion in the frontal and/or temporal lobes (see figures). Changes are usually bilateral, although may be asymmetric, with emphasis on either the left or right side. A normal scan, reported in about 10% of cases, or the presence of generalised atrophy with no frontotemporal emphasis does not preclude the diagnosis, although suggests a need for diagnostic caution. Sensitivity is slightly greater for functional (SPECT) than structural (MR) imaging, although specificity is reduced: frontotemporal hypoperfusion on SPECT is sometimes also seen in psychosis. Imaging changes need to be interpreted in the context of clinical history, physical and cognitive examination. Electromyography is valuable in confirming the presence of MND.

Neuropathology and Genetics

At post-mortem, atrophy of the frontal and anterior temporal lobes is typically evident macroscopically. The underlying histology is not uniform. Some cases are tauopathies, characterised by gliosis, tau inclusions and swollen cells, and conform to traditional pathological definitions of Pick's disease. Other cases are tau-negative but stain for ubiquitin. Ubiquitin-positive cases are classified into three sub-types.

Mutations have been found in some familial FTD cases in the tau gene and in other cases in the progranulin gene, both on chromosome 17. Tau mutations are associated with tau histopathology, and progranulin mutations with ubiquitin histology. These mutations account for less than half of all familial cases indicating that other genes remain to be discovered. Linkage to chromosome 9 has been demonstrated in FTD/MND.

Phenotypic variation: apathetic, disinhibited and stereotypic forms of FTD

The behavioural profile in FTD patients is not uniform. Some patients exhibit prominent apathy, loss of volition and affective blunting, which may be mistaken for depression. Others are impulsive, overactive, distractible, disinhibited and fatuous, more closely resembling hypomania. Disinhibited patients tend to become increasingly apathetic over the disease course. Yet, the different profiles are not solely a question of staging of disease, as apathy can be the earliest symptom. Performance on standard 'frontal' executive tests is typically more severely impaired in apathetic patients, who tend to show widespread frontal atrophy involving dorsolateral regions, than in disinhibited patients, who show relatively circumscribed atrophy of the orbital frontal lobes and temporal poles. Patients who present with social disinhibition may perform remarkably normally on cognitive tests, including executive tasks, during the early stages of disease. Executive deficits emerge with time.

Repetitive behaviours are common in FTD irrespective of phenotype. Nevertheless, there are some, relatively rare, patients in whom behavioural stereotypies are the striking and dominant characteristic. They may present with an obsessive preoccupation with a single issue, harp constantly on the same theme, and repeat constantly the same purposeless actions. In such patients a temporal and striatal emphasis of atrophy has been reported.

Related clinical syndromes: Progressive aphasia and semantic dementia

The behavioural disorder of FTD is one of a spectrum of pathologically-related clinical syndromes associated with focal atrophy of the anterior cerebral hemispheres. Progressive non-fluent aphasia is a disorder of expressive language resulting from atrophy of language areas of the left hemisphere. It may be linked to either tau and ubiquitin histopathology. Semantic dementia is a disorder of conceptual knowledge resulting from bilateral atrophy of the temporal lobes and associated with ubiquitin histopathology. Patients with semantic dementia no longer understand the meaning of words or significance of objects, and in the later stages may behave inappropriately (e.g. urinate in a waste bin) because of failure of object identification. Psychiatrists are more likely to encounter FTD than these other syndromes by virtue of its greater prevalence and the early behavioural/affective change. Nevertheless, some patients show overlapping symptomatology, indicating a need for awareness of these other clinical manifestations of focal cerebral degeneration.

Nomenclature and Nosology

Clinical and pathological heterogeneity has led to a bewildering array of terminology. “FTD” is now typically adopted in preference to the traditional “Pick’s disease” on the grounds that only a proportion of cases have Pick-type histopathology. The term “frontotemporal lobar degeneration” is frequently used as an umbrella term to encompass FTD (as described here), progressive non-fluent aphasia and semantic dementia, and incorporates both tau and ubiquitin types of histopathology. Confusingly, “FTD” is sometimes also used in this generic sense, with distinctions being made between frontal (behavioural) and temporal (semantic) variants. There is now evidence that clinical phenotype is a predictor of both subtype of ubiquitin histology and genetic mutation, suggesting the aetiological importance of clinical distinctions,

Diagnostic challenges in FTD

There are four categories of FTD patient who present a particular challenge for diagnosis: those with a) very youthful onset, b) very slow course c) affective presentation and d) psychotic presentation.

Youthful onset

Diagnosis is problematic only in so far as behavioural change arising in a patient in their 20s or 30s is likely to lead to a high index of suspicion of a psychiatric disorder and not of dementia. Clinicians may therefore be slow to consider the possibility of FTD. Nevertheless, very early onset cases typically present a florid picture of frontal lobe dysfunction, so that once considered and properly investigated, the diagnosis of FTD can be made with a high degree of confidence.

Slow course

More problematic are patients presenting in their 50s or 60s in whom the ‘frontal’ behavioural syndrome appears to progress very slowly or not at all. It is clear from genetically confirmed or pathologically proven cases that progression can indeed be extremely slow. On the other hand, not all slowly progressive/static cases are likely to have FTD. FTD-like symptoms may, for example, occur in people with long-standing traits of Asperger’s syndrome/autism spectrum disorder. The presence of frontotemporal atrophy demonstrated on brain imaging supports the diagnosis of FTD, whereas a continuing normal scan suggests the need for caution in making the diagnosis.

Affective presentation

In some patients, the frank behavioural disorder and loss of insight typical of FTD is heralded by a period of depression or anxiety. In other patients, the prodrome is a period of hypochondriacal preoccupation with somatic symptoms. The boundary between psychiatric and neurodegenerative disorder can be difficult to discern and it is only longitudinal evaluation that clarifies the diagnosis. Resistance to treatment of affective disorder may raise suspicion of underlying dementia.

Diagnostic challenges

- Very early onset - presentation in 20s or 30s
- Static or slow progression
- Affective presentation: depression, anxiety, hypochondriasis
- Psychotic presentation

Psychotic presentation

Psychosis is not a common feature of FTD. Nevertheless, there are rare patients who present to psychiatrists with a frank psychotic illness, which then evolves into the frontal lobe syndrome of FTD. The presence of frontotemporal atrophy on imaging, executive impairments demonstrated by neuropsychological evaluation, as well as the temporal evolution, can be helpful in distinguishing FTD presenting with psychosis, from psychosis mimicking FTD.

FTD and the law

Socially disruptive and antisocial behaviour are core features of FTD. Patients are oblivious to social conventions and their behaviour is not constrained by rules and laws of the land. It might be envisaged therefore that FTD patients would frequently come into contact with the police and forensic services. Brushes with the law do occur, although they are less common than might be expected. Apathy and lack of pre-meditation and forethought are undoubtedly contributory factors. Moreover, when infringements of the law occur the circumstances often make it clear that the patient is ill so that no charges are brought. For example, a patient who steals sweets from the supermarket may do so openly in full view of others, and proceed to eat them while making no attempt to leave the shop. The behaviour is more akin to that seen in a young child rather than a determined shoplifter. Patients' adherence to routine and tendency to wander fixed routes mean that they often become known within a neighbourhood and treated benignly.

Patients living alone are most vulnerable to prosecution because of the absence of a family member or advocate who can prevent, diffuse or explain deviant behaviour. The most common reasons for contact with the law are a) shoplifting, b) driving offences: driving without a licence, ignoring red lights, dangerous driving, c) harassment, d) sexual misdemeanours: indecent exposure, inappropriate touching, public masturbation and e) assault. Such behaviours typically reflect patients' general lack of social awareness. For example, accusations of indecent exposure may occur in people who have developed a habit of removing their clothes in public and wandering naked, in whom there is no sexual intent. Hypersexuality can occur although it is not common. When aggression occurs, it is typically in the context of the patient's wishes being thwarted: the patient lashes out at the person preventing them doing what they want.

Commentary on the Mental Health Commission Report of Mr G

A key criticism in the report on the care of Mr G was that the diagnosis of personality disorder made at the time of Mr G's initial contact with Mental Health Services was not placed under sufficient scrutiny. There are a number of features recorded in the Commission's report that would be strongly suggestive of FTD.

- There is clear evidence of decline in Mr G's behaviour, both from his premorbid state to his hospital admission in 2001 and from 2001 to 2004.
- His socially inappropriate behaviour extended outside the bounds of sexual behaviour: he urinated and defaecated in public, and became incontinent without apparent distress.
- He developed a preference for sweet foods, even being noted to eat sugar directly from the sugar bowl. He took other people's food.
- He was noted to wander.
- He developed physical signs of parkinsonism. His mother was said to have had 'Parkinson's disease' raising the possibility that his disorder was familial.
- The behavioural disorder was heralded by depression and anxiety.

Another criticism in the report is the reliance on the Mini-Mental state examination (MMSE) to exclude the presence of dementia. This point is worth emphasising. The MMSE does not tap frontal executive skills, and so is a poor indicator of FTD. Patients may achieve normal scores, despite significant behavioural and executive impairments. Neuropsychological assessment that includes examination of frontal executive skills is essential. It should be noted, however, that even normal performance on executive tests does not absolutely rule out a diagnosis of FTD, since in the early stages of disease some patients exhibit behavioural impairment without accompanying impairment in cognition (see section on Phenotypic variation, and case history 1).

The report mentions that Mr G had a brain scan in 2003, but that this did not alter the diagnosis of personality disorder. The result of the scan is not stated. A scan showing atrophy of the frontotemporal lobes would provide strong evidence for a degenerative disorder, whereas a normal scan would not firmly exclude a diagnosis of FTD.

The report criticises the failure to use structured psychological treatments in the management of Mr G. Management of challenging behaviour in FTD can be difficult. Nevertheless, structured behavioural techniques and recognition of the causes of aggressive outbursts can help. Mr G was reported to have assaulted staff members when they stopped him eating sugar direct from the bowl. This is a typical trigger for aggression in FTD: being obstructed from a desired course of action. FTD patients' behaviour is typically optimal in the context of a structured, non-confrontational environment.

Perhaps the most important implication of the Commission's report is that, contrary to prior assumptions, Mr G had no control over his behaviour. This is an important and central feature of FTD. Frontal lobe disease robs the patient of making informed decisions and judgements and of voluntary control over behaviour. Patients lack insight into their altered mental state.

Cognitive Assessment

The clinical history of progressively altered behaviour is key to the diagnosis of FTD. However, cognitive assessment, with demonstration of impairment in 'frontal' executive functions plays an important contributory role.

Cognitive Screening Instruments

The MMSE is a relatively blunt instrument, which has poor sensitivity to frontal lobe disturbances. The Addenbrooke's Cognitive Evaluation (ACE-R) (<http://pentorch.net>) and Montreal Cognitive Assessment (MoCA) (<http://www.mocatest.org>) are useful, freely available screening instruments for cognitive dysfunction. Both tap a wider range of cognitive abilities than the MMSE. The ACE-R incorporates the MMSE, is scored out of 100 and takes about 15 minutes to administer. Its 'frontal' executive component comprises two verbal fluency tasks (generating words beginning with P and names of animals). The MoCA takes about 10 minutes to administer and like the MMSE, is scored out of 30. It includes several tasks sensitive to frontal lobe function: a mini trail-making test, tests of attention, verbal fluency and abstraction (indicating the similarity between object pairs).

Frontal assessment batteries

There are several published test batteries specifically designed to assess frontal lobe functions. The most well known are the Behavioural Assessment of the Dysexecutive Syndrome (BADS) and the Delis-Kaplan Executive Function System (D-KEFS), both published by Pearson Assessment (<http://www.psychcorp.co.uk>)

'Bedside' Assessment of Frontal Lobe function

There may be situations, such as in a prison setting, where frontotemporal dementia is suspected yet no formal assessment tools are available. Reliance needs to be placed on behavioural observation, combined with simple bedside tests. Key behavioural features to note are a) blunted or fatuous affect, b) lack of concern for predicament, c) economy of effort, d) behavioural stereotypies, pacing and wandering, e) echolalia and perseveration. The following are simple tasks, sensitive to impairments in frontal lobe function.

Verbal fluency

- Generate names of animals in one minute
- Generate words beginning with letter 'F' in one minute.
Proper names are not allowed.

Design fluency

- Draw different abstract designs constructed from 4 lines
(can be straight or curved)

Proverb and sentence interpretation

- Provide definition of common proverbs (e.g. every cloud has a silver lining)
- Answer yes/no questions (e.g. would you cut meat with a spoon?
would you use a saw to cut wood?)

Similarities

- Identify ways in which two related words are similar (e.g. orange-banana; dog-lion)

Sequential commands

- Point to four objects or body parts in sequence

Luria motor tasks

- Sequencing: Produce, following demonstration, a repeated series of hand postures (e.g. palm-fist-edge)
- Alternating movements: Produce unimanual and bimanual rapid alternating movements (e.g. palm-up, palm-down; arm extension with palm down, arm extension with clenched fist)
- Hand tapping (when the examiner taps once the patient taps twice and vice versa)

It should be emphasised that 'frontal' tests are sensitive but not specific to frontal lobe dysfunction. Poor scores on a verbal fluency or proverb test, for example, could arise because of language disturbance, poor education, depressed mood or wilful non-compliance. Key 'frontal' characteristics to look out for are a) concreteness of thought and self-referential responses, b) lack of adherence to task goal/rule violations, c) faulty sequencing and d) perseveration.

Concrete responses are most obvious in proverb tasks (e.g. "Every cloud has a silver lining" interpreted in terms of the weather). However, concreteness may be elicited too by more general sentence comprehension tasks (e.g. Qu. Would you use a saw to cut wood? Ans. "I leave that kind of job to my husband"). In category fluency the patient may itemise their own pets rather than animals in general. In design fluency, the patient may draw concrete objects (e.g. a house) despite instructions that designs should be non-representational. In the Similarities task, the patient may itemise differences (e.g. "An orange is round and a banana is long") despite instructions to identify a commonality.

Rule violations are most commonly elicited in open-ended tasks such as verbal and design fluency. The patient may give Proper names when explicitly told not to do so (e.g. F words: "Frank, Fiona") or produce word associates that do not conform to the letter rule (e.g. F words: "fish, chips"). In design fluency, the patient may draw concrete objects despite being told not to do so, or designs constructed from more than 4 lines, ignoring the 4-line rule. In fluency tests the patient may insert personal comments or anecdotes (e.g. F words: "fish - we get ours from Tesco's"), indicating loss of adherence to the task goal (i.e. to produce as many items as possible in one minute).

‘Bed-side’ assessment of frontal lobe function

- ‘Frontal’ lobe tests are sensitive to frontal lobe dysfunction BUT they are NOT specific – failure can arise for other reasons
- Need to take account of qualitative features of performance as well as test scores
 - economy, lack of persistence, lack of concern for accuracy, distractibility, concrete responses, perseveration, echolalia, verbal and motor stereotypies
- Frontal executive functions can be preserved in early FTD

Sequencing problems may be elicited by simple tasks such as pointing to objects or body parts in order, and particularly by the more challenging Luria motor tests.

Perseveration may be elicited in both the verbal (e.g. verbal fluency) and nonverbal (e.g. design fluency, Luria motor tasks) domain. Motor perseveration may occur at an elementary level (e.g. multiple repetitions of palm-up response, before shifting to palm-down action), or at a higher-order level (e.g. patient successfully completes palm-up, palm-down actions, but when subsequently asked to copy a fist-palm action, continues to perseverate the earlier palm-up, palm-down action)

Case Histories

Case 1

Mrs A, formerly an industrious business woman, came to psychiatric attention at the age of 54 years. Over the preceding months she had become increasingly apathetic, lacking in motivation and self-care. If left to her own devices she would spend all day doing nothing. There was an episode of urinary incontinence, which she shrugged off saying that she “could not be bothered” to go to the bathroom. There was no relevant previous medical or family history. She was initially suspected of being depressed. However, her lack of response to therapy and continuing decline raised the suspicion of a neurodegenerative disorder. Two years after onset of her symptoms she was referred to a specialist early onset dementia clinic. Neurological examination was normal aside from ‘frontal’ primitive reflexes. Neuropsychological test performance was characterised by economy of effort and poor persistence on tasks. She showed profound impairment on frontal executive tests, with striking perseveration of both verbal and motor responses. There was no primary aphasia, perceptual or spatial disorder and she was oriented in time and place. A SPECT scan showed bilateral frontal hypoperfusion. A diagnosis of FTD was made.

Points of note

- The early clinical features suggested affective disorder
- The clinical presentation of FTD may be of apathy and inertia rather than frank social disinhibition

Over the ensuing years speech output became progressively more attenuated, echolalic and perseverative, culminating in total mutism. She became gluttonous, with a fondness for sweet foods leading to obesity. In the latter stages, she failed to eat, attributable to her profound apathy, resulting in dramatic weight loss. Her affect was blunted and unconcerned. Mild parkinsonian signs emerged late in the disease course. She died of bronchopneumonia 7 years after onset of symptoms. Post-mortem examination of the brain demonstrated severe, circumscribed atrophy, particularly affecting dorsolateral frontal regions, and associated with tau (Pick-type) histopathology.

Case 2

At the age of 48 Mr L began to show progressive alterations in his character and social conduct. Previously, a warm, sociable and responsible citizen, he became increasingly puerile, taking pleasure in childish jokes and pranks. He embarrassed his family by socially inappropriate remarks and disinhibited conduct. He neglected domestic and occupational responsibilities for which he showed no concern. He adopted a ritualistic daily routine. Repetitive behaviours included incessant whistling of the same tune and stereotyped use of favoured phrases (e.g. “not bad for a lad”). He hoarded sweets and ate to excess. He was referred initially to a psychiatrist who suspected an organic disorder. He was seen by a neurologist, at the age of 52 years, four years after onset of symptoms. Neurological examination was entirely normal and detailed neuropsychological assessment was unremarkable. He scored 30/30 on the MMSE. Nevertheless, the profile of character and behavioural change was strongly suggestive of a diagnosis of FTD. In keeping with the diagnosis, structural MR imaging revealed atrophy most marked in the temporal lobes and functional SPECT imaging revealed frontotemporal hypoperfusion. There was a strong family history of a similar disorder indicative of an autosomal dominant pattern of inheritance. Molecular genetic screening elicited a +16 splice site mutation in the tau gene on chromosome 17, providing confirmation of the diagnosis of FTD.

Points of note

- Behavioural changes occurred in the absence of significant cognitive change
- The mini-mental state examination was an insensitive measure of frontal lobe dysfunction
- Interpersonal behaviour was superficially regarded as acceptable, despite the long history of progressive behavioural change

Mr L's condition progressed very slowly. Fourteen years after onset of symptoms, Mr L continued to be physically well and only mild 'frontal' executive impairments were demonstrable on cognitive testing, together with some naming difficulties suggestive of semantic impairment. Nevertheless, his behavioural disorder increased. He began taking goods from the local supermarket without paying for them. The pilfered items were generally of no practical value (e.g. two right footed shoes, of different sizes), but he would hoard them at home. He was arrested and charged with shoplifting. The police officer considered that he "seemed alright", and was unwilling to accept that he had a degenerative brain disorder. Supportive letters from neurological and psychiatric teams helped to divert the case from prosecution.

Case 3

Mr P, formerly a successful business man, with no relevant family or previous medical history, presented to psychiatric services at the age of 35, because of preoccupations with the breakdown of a long-standing relationship. He was diagnosed variously with anxiety disorder, depression and inability to cope with the separation from his partner. The preoccupation intensified over the next two years, acquiring delusional proportions. He became involved in court proceedings because of harassment of his partner, and acquired convictions for public order offences. He lost contact with psychiatric services because of non-compliance. When he was 38 years old his home was raided by the police, following a tip-off that drugs may be found. Mr P was found in a state of neglect, surrounded by piles of empty orange juice cartons. Of greater interest to the police was the discovery of a sawn-off shot gun and ammunition, resulting in Mr P's arrest. He was initially held in custody but because of his obviously abnormal behaviour was transferred to a regional forensic psychiatry service. There he showed markedly stereotyped behaviour, including repeated spitting and tapping of the walls, and verbatim monologues relating to his ex-partner. The bizarre behaviour in the absence of clear cut symptoms of mood disorder or psychosis led to a neurological referral. Neurological examination revealed parkinsonian signs of limb rigidity and loss of facial expression. Neuropsychological assessment revealed impaired attention, perseveration and stereotyped responses indicative of frontal lobe dysfunction. Structural MR imaging showed frontotemporal lobe atrophy and SPECT showed frontotemporal hypoperfusion. A diagnosis was made of FTD. He remained in forensic psychiatric care for 12 months because of difficulty in finding an alternative placement in view of his young age. He was ultimately transferred to residential care, where he required one-to-one care. His condition deteriorated rapidly. He showed restless pacing, hyperorality (Kluver-Bucy syndrome), including coprophagia, and he was doubly incontinent. No social interaction was possible. He died aged 40 years. The final diagnosis was of FTD.

Points of note

- Anxiety and preoccupation preceded the more obvious signs of frontal lobe dysfunction.

Clinical Diagnostic Criteria for FTD

Box 7

Core diagnostic features

- Insidious onset and gradual progression
- Early decline in social interpersonal conduct
- Early impairment in regulation of personal conduct
- Early emotional blunting
- Early loss of insight

Supportive diagnostic features

Behavioural disorder

- Decline in personal hygiene and grooming
- Mental rigidity and inflexibility
- Distractibility and impersistence
- Hyperorality and dietary change
- Perseverative and stereotyped behaviour
- Utilisation behaviour

Speech and Language

Altered speech output (as spontaneity and economy of speech, press of speech), stereotypy of speech, echolalia, perseveration, mutism.

Physical signs

Primitive reflexes, incontinence, akinesia, rigidity and tremor, low and labile blood pressure

Bulbar palsy, muscular weakness and wasting, fasciculations (associated with motor neurone disease)

Investigations

Neuropsychology: significant impairment on frontal lobe tests in the absence of severe amnesia, aphasia or perceptuospatial disorder

EEG: normal on conventional EEG despite clinically evident dementia

Brain imaging (structural or functional): predominant frontal and/or anterior temporal abnormality.

Demographics

Onset before 65 years; positive family history of similar disorder in first degree relative

Neurology 1998; 51: 1546-54

Further reading

This bibliography is organised according to topic. Review articles and multi-centre, international consensus statements are cited first in each section, followed by other studies, arranged in chronological order of publication.

Overview

Neary D, Snowden JS, Mann DMA. Frontotemporal dementia. *Lancet Neurology* 2005; 4:771-80. (review article)

Diagnostic Criteria

Lund and Manchester groups. Consensus statement. Clinical and neuropathological criteria for frontotemporal dementia. *J Neurol Neurosurg Psychiatry* 1994;57:416-8. (consensus statement)

Neary D, Snowden JS, Gustafson L, et al. Frontotemporal lobar degeneration: a consensus on clinical diagnostic criteria. *Neurology* 1998;51:1546-54. (consensus statement)

Rosen HJ, Hartikainen KM, Jagust W, et al. Utility of clinical criteria in differentiating frontotemporal lobar degeneration (FTLD) from AD. *Neurology* 2002;58:1608-15.

Knopman DS, Boeve BF, Parisi JE, et al. Antemortem diagnosis of frontotemporal lobar degeneration. *Ann Neurol* 2005; 57: 480-8.

Pijnenburg, Y. A., Mulder, J. L., van Swieten, J. C., et al. Diagnostic accuracy of consensus diagnostic criteria for frontotemporal dementia in a memory clinic population. *Dement Geriatr Cogn Disord* 2008; 25: 157-64

Demographics

Ratnavalli E, Brayne C, Dawson K, Hodges JR. The prevalence of frontotemporal dementia. *Neurology* 2002; 58: 1615-21.

Rosso SM, Donker KL, Baks T, et al. Frontotemporal dementia in The Netherlands: patient characteristics and prevalence estimates from a population-based study. *Brain* 2003;126:2016-22.

Grasbeck A, Englund E, Horstmann V, et al. Predictors of mortality in frontotemporal dementia: a retrospective study of the prognostic influence of pre-diagnostic features. *Int J Geriatr Psychiatry* 2003;18:594-601.

Ikeda M, Ishikawa T, Tanabe H. Epidemiology of frontotemporal lobar degeneration. *Dement Geriatr Cogn Disord* 2004;17:265-8.

Snowden JS, Neary D, Mann DM. Autopsy proven sporadic frontotemporal dementia due to microvacuolar-type histology with onset at 21 years of age. *J Neurol Neurosurg Psychiatry* 2004;75:1337-9.

Behaviour

Snowden JS, Neary D. Neuropsychiatric aspects of frontotemporal dementias. *Curr Psychiat Rep* 1999; 1: 93-98 (review article)

Mendez, M. F., Lauterbach, E. C., Sampson, S. M. An evidence-based review of the psychopathology of frontotemporal dementia: a report of the ANPA Committee on Research. *J Neuropsychiatry Clin Neurosci* 2008; 20: 130-49 (review article)

Wittenberg, D., Possin, K. L., Rascovsky, K., et al. The early neuropsychological and behavioral characteristics of frontotemporal dementia. *Neuropsychol Rev* 2008; 18: 91-102 (review article)

Ames D, Cummings JL, Wirshing WC, et al. Repetitive and compulsive behavior in frontal lobe degenerations. *J Neuropsychiatry Clin Neurosci* 1994;6:100-13.

Miller BL, Darby AL, Swartz JR, et al. Dietary changes, compulsions and sexual behaviour in frontotemporal degeneration. *Dementia* 1995;6:195-9.

Bozeat S, Gregory CA, Lambon Ralph MA, Hodges JR. Which neuropsychiatric and behavioural features distinguish frontal and temporal variants of frontotemporal dementia and Alzheimer's disease. *J Neurol Neurosurg Psychiatry* 2000;69:178-86.

Bathgate D, Snowden JS, Varma A, et al. Behaviour in frontotemporal dementia, Alzheimer's disease and vascular dementia. *Acta Neurol Scand* 2001;103: 367-78.

Snowden JS, Bathgate D, Varma A, et al. Distinct behavioural profiles in frontotemporal dementia and semantic dementia. *J Neurol Neurosurg Psychiatry* 2001;70:323-32.

Ikeda M, Brown J, Holland AJ, et al. Changes in appetite, food preference and eating habits in frontotemporal dementia and Alzheimer's disease. *J Neurol Neurosurg Psychiatry* 2002;73:371-6.

Nyatsanza S, Shetty T, Gregory C, et al. A study of stereotypic behaviours in Alzheimer's disease and frontal and temporal variant frontotemporal dementia. *J Neurol Neurosurg Psychiatry* 2003;74:1398-402.

Cognition: executive functions, social cognition and emotion processing

Lough S, Gregory C, Hodges JR. Dissociation of social cognition and executive function in frontal variant frontotemporal dementia. *Neurocase* 2001;7:123-30.

Gregory C, Lough S, Stone V, et al. Theory of mind in patients with frontal variant frontotemporal dementia and Alzheimer's disease: theoretical and practical implications. *Brain* 2002;125:752-64.

Keane J, Calder AJ, Hodges JR, Young, AW. Face and emotion processing in frontal variant frontotemporal dementia. *Neuropsychologia* 2002; 40: 655-65.

Snowden JS, Gibbons ZC, Blackshaw A, et al. Social cognition in frontotemporal dementia and Huntington's disease. *Neuropsychologia* 2003;41:688-701.

Thompson JC, Stopford CL, Snowden JS, Neary D. Qualitative neuropsychological performance characteristics in frontotemporal dementia and Alzheimer's disease. *J Neurol Neurosurg Psychiatry* 2005;76:920-7.

Lough, S., Kipps, C. M., Treise, C., et al. Social reasoning, emotion and empathy in frontotemporal dementia. *Neuropsychologia* 2006; 44: 950-58

Kipps, C. M., Nestor, P. J., Acosta-Cabronero, J., et al. Understanding social dysfunction in the behavioural variant of frontotemporal dementia: the role of emotion and sarcasm processing *Brain* 2009

Brain imaging

Talbot PR, Lloyd JJ, Snowden JS, et al. A clinical role for 99mTc-HMPAO SPECT in the investigation of dementia? *J Neurol Neurosurg Psychiatry* 1998; 64: 306-13.

Rombouts SA, van Swieten JC, Pijnenburg YA, et al. Loss of frontal fMRI activation in early frontotemporal dementia compared to early AD. *Neurology* 2003;60:1904-8.

Salmon E, Garaux G, Delbeuck X, et al. Predominant ventromedial frontopolar metabolic impairment in frontotemporal dementia. *Neuroimage* 2003; 20: 435-40.

Whitwell JL, Anderson VM, Scahill RI, et al. Longitudinal patterns of regional change on volumetric MRI in frontotemporal lobar degeneration. *Dement Geriatr Cogn Disord* 2004;17: 307-10.

Kipps, C. M., Davies, R. R., Mitchell, J. et al. Clinical significance of lobar atrophy in frontotemporal dementia: application of an MRI visual rating scale *Dement Geriatr Cogn Disord*; 2007; 23: 334-42

McNeill, R., Sare, G. M., Manoharan, M. et al. Accuracy of single-photon emission computed tomography in differentiating frontotemporal dementia from Alzheimer's disease. *J Neurol Neurosurg Psychiatry* 2007; 78: 350-5

Clinical association with motor neurone disease

Ringholz, G. M., Greene, S. R. The relationship between amyotrophic lateral sclerosis and frontotemporal dementia *Curr Neurol Neurosci Rep* 2006; 6: 387-92

Neary D, Snowden JS, Mann DMA, et al. Frontal lobe dementia and motor neuron disease. *J Neurol Neurosurg Psychiatry* 1990; 53: 23-32.

Lomen-Hoerth, C., Anderson, T., Miller, B. The overlap of amyotrophic lateral sclerosis and frontotemporal dementia *Neurology* 2002; 59: 1077-9

Pathology and clinical-pathological relationships

Cairns, N. J., Bigio, E. H., Mackenzie, I. R. et al. Neuropathologic diagnostic and nosologic criteria for frontotemporal lobar degeneration: consensus of the Consortium for Frontotemporal Lobar Degeneration *Acta Neuropathol* 2007; 114: 5-22 (consensus statement)

Mackenzie, I. R., Neumann, M., Bigio, E. H. et al. Nomenclature for neuropathologic subtypes of frontotemporal lobar degeneration: consensus recommendations. *Acta Neuropathol* 2009;117:15-8 (consensus statement)

Hodges JR, Davies RR, Xuereb JH, et al. Clinicopathological correlates in frontotemporal dementia. *Ann Neurol* 2004;56:399-406.

Snowden JS, Neary D, Mann DMA. Frontotemporal lobar degeneration: clinical and pathological relationships. *Acta Neuropathol* 2007; 114: 31-8.

Genetics and clinical-genetic relationships

van Swieten, J. C., Heutink, P. Mutations in progranulin (GRN) within the spectrum of clinical and pathological phenotypes of frontotemporal dementia *Lancet Neurol* 2008; 7:965-74. (review article)

Hutton M, Lendon CL, Rizzu P, et al. Association of missense and 5'-splice-site mutations in tau with the inherited dementia FTDP-17. *Nature* 1998; 393: 702-5.

Baker M, Mackenzie IRA, Pickering-Brown SM, et al. Mutations in Progranulin cause tau-negative frontotemporal dementia linked to chromosome 17. *Nature* 2006; 442, 916-9.

Pickering-Brown SM, Richardson AMT, Snowden JS, et al. Inherited frontotemporal dementia in nine British families associated with intronic mutations in the tau gene. *Brain* 2002; 125: 732-51.

Snowden JS, Pickering-Brown SM, Mackenzie IR, et al. Progranulin gene mutations associated with frontotemporal dementia and progressive non-fluent aphasia. *Brain* 2006; 129: 3091-102.

Morita, M., Al-Chalabi, A., Andersen, P. M. A locus on chromosome 9p confers susceptibility to ALS and frontotemporal dementia *Neurology* 2006; 66: 839-44

Rademakers R, Baker M, Gass J, et al. Phenotypic variability associated with progranulin haploinsufficiency in patients with the common 1477C-T (Arg493X) mutation: an international initiative. *Lancet Neurology* 2007; 6: 857-68.

Pickering-Brown SM, Rollinson S, Du Plessis D, et al. Frequency and clinical characteristics of progranulin mutation carriers in the Manchester Frontotemporal Lobar Degeneration cohort: Comparison to patients with MAPT and no known mutations. *Brain* 2008; 131: 721-31.

Seelaar, H., Kamphorst, W., Rosso, S. M., et al. Distinct genetic forms of frontotemporal dementia *Neurology* 2008; 71: 1220-6

Treatment

Freedman, M. Frontotemporal dementia: recommendations for therapeutic studies, designs, and approaches. *Can J Neurol Sci* 2007; 34Suppl1 S118-24 (review article)

Huey, E. D., Armstrong, N., Momeni, P., Grafman, J. Challenges and new opportunities in the investigation of new drug therapies to treat frontotemporal dementia *Expert Opin Ther Targets* 2008; 12: 1367-76 (review article)

Bowen, D. M., Procter, A. W., Mann, D. M., et al. Imbalance of a serotonergic system in frontotemporal dementia: implication for pharmacotherapy *Psychopharmacology (Berl)* 2008; 196: 603-10.

Cognitive Screening Instruments

ACE

Dudas, R.B., Berrios, G.E., Hodges, J.R. The Addenbrooke's cognitive examination (ACE) in the differential diagnosis of early dementias versus affective disorder. *Am J Geriatr Psychiatry* 2005; 13: 218-26.

Mioshi, E., Dawson, K., Mitchell, J. et al. The Addenbrooke's Cognitive Examination Revised (ACE-R): a brief cognitive test battery for dementia screening. *Int J Geriatr Psychiatry* 2006; 21: 1078-85.

MoCA

Nasreddine, Z.,S., Phillips, N.A., Bedirian, V., et al. The Montreal Cognitive Assessment. MoCA: A brief screening tool for mild cognitive impairment. *J Am Geriatr Soc* 2005; 53: 695-9.

Multiple-Choice Questions

What do you know about frontotemporal dementia?

- 1. Frontotemporal dementia is**
 - a) a viral disease
 - b) a prion disease
 - c) a metabolic disease
 - d) a neurodegenerative disease
 - e) a disease of the brain's blood supply

- 2. The earliest recorded onset is**
 - a) 21 years
 - b) 28 years
 - c) 32 years
 - d) 35 years
 - e) 40 years

- 3. The average duration from onset to death is about**
 - a) 2 years
 - b) 4 years
 - c) 8 years
 - d) 12 years
 - e) 16 years

- 4. The incidence is**
 - a) much higher in men than women (ratio 4:1)
 - b) much lower in men than women (ratio 1:4)
 - c) somewhat higher in men than women (ratio 3:2)
 - d) somewhat lower in men than women (ratio 2:3)
 - e) comparable in men and women (ratio 1:1)

- 5. FTD is known to be influenced by**
 - a) genetic factors
 - b) educational background
 - c) geography
 - d) cultural factors
 - e) diet

- 6. The earliest symptoms are typically**
 - a) poor short and long-term memory
 - b) personality and behavioural change
 - c) physical slowing and parkinsonism
 - d) mental slowing and aphasia
 - e) agnosia and apraxia

- 7. Affect is most commonly described as**
 - a) warm, affectionate
 - b) worried, concerned
 - c) irritable, paranoid
 - d) elated, grandiose
 - e) blunted, fatuous

8. A characteristic feature is

- a) limb weakness
- b) spatial impairment
- c) repetitive behaviour
- d) deluded ideation
- e) misperception

9. FTD patients frequently develop a preference for

- a) sweet foods
- b) savoury foods
- c) highly spiced foods
- d) soft or liquid foods
- e) brightly coloured foods

10. Incontinence

- a) is not a feature of FTD at any stage
- b) only occurs in late-stage disease, causing patient distress
- c) only occurs in late-stage disease, without patient distress
- d) may occur even in early disease, causing patient distress
- e) may occur even in early disease without patient distress

11. There is an association between FTD and

- a) motor neurone disease
- b) epilepsy
- c) multiple sclerosis
- d) head trauma
- e) encephalitis

12. 'Frontal' executive cognitive deficits are demonstrable

- a) in all patients in early stage disease
- b) in most patients in early stage disease
- c) occasionally in early stage disease
- d) only in middle-stage disease
- e) only in late-stage disease

13. Mini-mental state examination scores in FTD

- a) are always preserved throughout the disease course
- b) are usually preserved throughout the disease course
- c) may be preserved throughout the disease course
- d) may be preserved in early stage disease
- e) are never preserved

14. Atrophy, demonstrated by structural MR imaging

- a) is always symmetrical, affecting the left and right hemispheres equally
- b) is typically bilateral but may be asymmetric, affecting the left and right hemispheres to different degrees
- c) usually affects the left hemisphere more than the right
- d) usually affects the right hemisphere more than the left
- e) is usually unilateral, affecting one hemisphere only

15. The presence of frontotemporal atrophy on neuroimaging

- a) is alone sufficient to make a diagnosis of FTD
- b) is a requirement for diagnosis, in addition to the clinical features
- c) provides strong support for the diagnosis
- d) has limited diagnostic value
- e) has no diagnostic role

16. At end-stage disease the emphasis of atrophy on the frontal and temporal lobes

- a) is no longer evident
- b) is only occasionally detectable on microscopic examination
- c) is usually detectable microscopically but not to the naked eye
- d) is usually visible to the naked eye
- e) is always visible to the naked eye

17. The clinical symptoms and signs in FTD patients

- a) are virtually identical in all patients
- b) are variable, there being identifiable phenotypic variations
- c) are different in men and women
- d) tend to fluctuate from one day to the next
- e) are so diverse that no identifiable patterns can be described

18. Psychosis in FTD

- a) never occurs
- b) is rare and only occurs in late-stage disease
- c) is rare but may be a presenting symptom
- d) is seen in about 50% of patients
- e) is present in most patients at some time during the disease course

19. People with FTD

- a) conform to culturally accepted rules of social conduct
- b) occasionally violate social rules but these do not lead to criminal conviction
- c) occasionally violate social rules and these may lead to criminal convictions
- d) frequently violate social rules, but criminal convictions are rare
- e) frequently violate social rules of conduct, which often lead to criminal convictions

20. People with FTD

- a) have insight and voluntary control over their behaviour throughout the disease course
- b) have insight and voluntary control over their behaviour in the early and middle stages of disease
- c) have insight throughout the disease course but reduced voluntary control over their behaviour
- d) have insight in the early and middle stages but reduced voluntary control over their behaviour
- e) have reduced insight and voluntary control over their behaviour even in the early stages

Multiple-Choice Answers

1. d
2. a
3. c
4. e
5. a
6. b
7. e
8. c
9. a
10. e
11. a
12. b
13. d
14. b
15. c
16. d
17. b
18. c
19. d
20. e



The Forensic Network
The State Hospital
Carstairs
Tel: 01555 842018
www.sofmh.scot.nhs.uk